



Gebрил OH^{1*}, Cheong SS², Hardcastle AJ², Abdelraouf ER¹, Eid SR³ and Elsaied M¹

¹Medical Division, National Research Centre, Cairo, Egypt

²Institute of Ophthalmology, University College London, UK

³Pediatric department, Research Institute of Ophthalmology, Cairo, Egypt

Dates: Received: 27 May, 2017; Accepted: 01 July, 2017; Published: 03 July, 2017

*Corresponding author: Ola Hosny Gebрил, Medical Division, National Research Centre, Cairo, Egypt, Tel: +2 01157583452, E-Mail: Olahossny@hotmail.com

Keywords: Eye; Anterior chamber; Mental retardation; Genes

<https://www.peertechz.com>

Case Report

Absence of *CHRD1* and *FOXC1* sequence changes in two brothers with Megalocornea-Mental Retardation Syndrome

Abstract

Megalocornea is a defining feature of megalocornea-mental retardation (MMR) syndrome also called Neuhäuser syndrome, a rare condition of unknown etiology.

Here we describe a family with two sons, who were diagnosed with megalocornea, mild mental subnormality and microcephaly, in addition to limb anomalies in the form of clinodactyly in the younger brother, while extradigit and clinodactyly was seen in the older brother. Parents are second degree cousins with no obvious family history of similar problems. Mutations in *CHRD1* are known to cause X-linked megalocornea (MGC1) and *FOXC1* mutations cause a wide range of syndromic or non-syndromic anterior segment dysgeneses (ASD) phenotypes. Sanger sequencing of *CHRD1* and *FOXC1* did not identify any potential disease causing variants in this family.

Conclusions: Megalocornea-mental retardation (MMR) syndrome is a genetically and phenotypically heterogeneous condition. In this Egyptian family, *CHRD1* and *FOXC1* have been excluded as the cause. Next generation sequencing is required to identify the genetic cause of the syndrome in this family.

Background

X-linked megalocornea (MGC1) is a genetically homogeneous condition, characterized by congenital bilateral enlarged corneas with a horizontal white-to-white diameter of ≥ 13 mm (after the age of 2 years), deep anterior chamber depth and reduced central corneal thickness (CCT) without increased intraocular pressure (IOP). Later onset clinical features include mosaic corneal degeneration, arcus juvenilis, lens dislocation, mild iris atrophy with pigment dispersion, and pre-senile cataracts. MGC1 is caused by mutations in the *CHRD1* (chordin-like 1) gene [1-3]. *CHRD1* encodes ventroptin, a secreted bone morphogenic protein (BMP) antagonist [4] and is expressed in the developing human cornea and anterior segment [1].

Megalocornea-mental retardation (MMR) syndrome is a rare and phenotypically heterogeneous condition, in which megalocornea is a defining feature. Extraocular features associated with MMR include intellectual disability (ID), hypotonia, seizures, and craniofacial abnormalities. Clinical features of previously reported MMR patients are summarized in Table 1. Due to the consistent presentation of megalocornea

and ID in MMR patients, del Giudice suggested that these two features should be the minimal diagnostic criteria for MMR syndrome. Other features such as short stature, seizures, neurological symptoms, microcephaly or macrocephaly, and minor anomalies are considered as additional clinical manifestations [5]. Transient hypothyroidism, epilepsy, cerebral palsy with choreoathetotic movements, and brain malformations have also been described previously [6]. The genetic cause of MMR is still poorly understood. A previous study identified a missense *CHRD1* mutation in a patient with MMR syndrome. However, the lack of extraocular features in other MGC1 patients with *CHRD1* mutations suggests that the *CHRD1* mutation is only causative of the megalocornea phenotype but not the associated extraocular manifestations [3].

FOXC1 (Fork-head box C1) is a member of the forkhead family of transcription factors, which has a major role in epithelial-mesenchymal transition, a process by which epithelial cells lose cell-to-cell adhesion and migrate at various stages of eye and nervous system development [7]. Mutations in the *FOXC1* gene have been reported to cause a spectrum of autosomal dominant anterior segment dysgeneses (ASD),

Table 1: Clinical features of MMR syndrome as described in various studies.

Study	Number of cases	Mental and motor retardation	Megalocornea	Hypotonia	Craniofacial	Epilepsy/EEG	Neuroimaging
					Abnormalities		Abnormalities
Frank et al. 1973 [15]	1	1	1	0	1	0	0
Neuhauser et al. 1975 [16]	7	7	4	5	7	4	0
Ohno et al. 1978 [17]	1	Not specified	Not specified	Not specified	Not specified	Not specified	Not specified
Schmidt R, Rapin, 1981 [18]	2	2	1	2	2	1	0
Del Giudice et al. 1987 [5]	2	2	1	2	2	1	0
Raas-Rothschild et al. 1988 [19]	1	1	1	0	1	0	0
Grønbech-Jensen 1989 [20]	1	1	1	1	1	0	0
Frydman et al. 1990 [21]	2	2	2	2	2	0	1
Kimura et al. 1991 [22]	1	1	1	1	0	1	1
Temtamy et al. 1991 [23]	3	3	3	0	3	0	0
Santolaya et al. 1992 [24]	1	1	1	1	1	0	0
Verloes et al. 1993 [25]	4	4	4	1	4	2	1
Antinolo et al. 1994 [26]	1	1	1	1	1	0	0
Gibbs et al., 1994 [27]	2	2	0	2	0	0	1
Barisic et al. 1996 [28]	1	1	1	1	1	1	1
Naritomi et al. 1997 [29]	1	1	1	Not specified	Not specified	Not specified	1
Tominaga et al. 1999 [30]	1	1	1	0	1	1	0
Sarkozy et al. 2002 [31]	1	1	1	1	1	1	1
Balci et al. 2002 [32]	2	2	2	2	2	Not specified	1
Derbent et al. 2004 [33]	1	1	1	1	1	0	1

including Axenfeld-Rieger syndrome (ARS), Rieger anomaly, Peters anomaly, primary congenital glaucoma (PCG), iris hypoplasia, aniridia, with or without extraocular features such as heart defects, craniofacial abnormalities and pituitary abnormalities [8-11]. Variable expressivity and incomplete penetrance for the associated phenotypes have also been observed [12-14].

Study Subjects and Clinical Description

All studies were conducted in accordance with the principles of the Declaration of Helsinki. The study was approved by the local ethics committees. Informed written consent, including permission to publish photographs, was obtained from all participating individuals or parental guardians on behalf of the minors enrolled in this study. Blood samples were donated and genomic DNA was extracted from peripheral blood lymphocytes using conventional methodologies. Patients were clinically assessed by experienced ophthalmologists. Standard evaluation consisted of detailed ophthalmic examination, and the additional measurement of the axial length of the eye and imaging of the anterior segment of the eye were performed. The affected brothers had standard MRI with a 1.5 Tesla scanner. In the younger brother, MRI showed mild brain atrophy, and retro-cerebellar cyst (Figure 1). Metabolic screening as well as abdominal and pelvic ultrasound were normal. Thyroid profile and EEG showed no deviations from normal. In the older brother, brain scan, thyroid profile and EEG were normal.

The younger brother was born to unaffected parents who are first cousins. He presented at the age of 6 months with delayed developmental milestones (head support by 10 months) and decreased weight gain with no history of convulsions. Dysmorphic features, hypertelorism, prominent ears, and tower shaped head were noted in addition to clinodactyly. Following initial presentation, progressive delay in developmental milestones in relation to age was encountered.

He is the product of normal pregnancy with no complications, born by normal vaginal delivery, birth weight was 3.000 kg with no neonatal unit admission needed. The mother had taken folic acid supplement in the 1st trimester and inconsistent iron and calcium supplements. Foetal movements were felt by 16th week gestation with normal frequency and normal pregnancy scans. He is currently (2 years of age) suffering delayed walking (walking with support) and speech is developing more or less appropriately (about 10 words).

Hypertelorism, megalocornea, long philtrum, broad nasal root, recession of chin and forehead, fusiform fingers of hands, clinodactyly 2nd-3rd fingers (Lt hand) are evident (Figure 2). Complete simian crease in the left hand and low set prominent ears are present. Mouth examination showed normal palate, uvula and teeth. He has evidence of scoliosis with normal abdomen and chest.

Neurological examination revealed decreased motor power in both upper and lower limbs (grade II to grade IV) with moderate hypotonia, and normal deep reflexes. No obvious abnormalities in external genitalia were seen.

Ophthalmological examination revealed a corneal diameter of 14mm in Rt eye and 15 mm in left eye, moderate myopia, hypotrichosis, normal ocular reflexes with normal fundus and intraocular pressure. Head circumference was 43.5 cm (far < 5th), Height was 82 cm (0.4th) and weight was 8.5 kg (<0.4th).

The older brother has better developmental history with mild delay compared to the younger brother. He has 5 years, increased corneal diameter (13mm bilaterally), normal fundus, myopia with right convergent squint, hypertelorism, long philtrum, and mild hypotonia with normal reflexes (Figure 3).

Broad nasal root was evident, with history of an extra finger beside the little finger on the left hand, which was removed at the age of 6 months. There were variable toe insertion levels

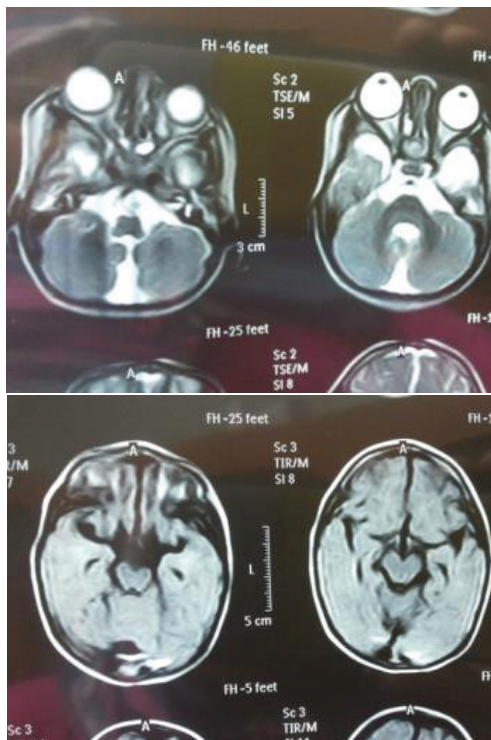


Figure 1: Brain MRI scan of younger sibling revealed reduced volume of white matter and retro-cerebellar cyst.

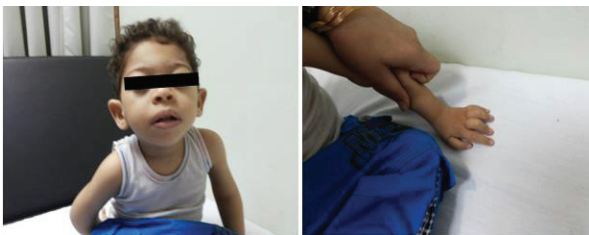

Figure 2: Younger brother presented with megalocornea, prominent ears, tower head (left panel); and clinodactyly of the 2nd and 3rd fingers (right panel).

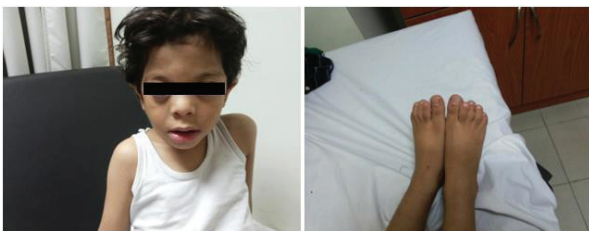


Figure 3: Older brother, presented with megalocornea, broad nasal root, hypertelorism, almond-shaped eyes and right convergent squint (left panel); variable toe insertion levels in both feet (right panel).

in both feet. Chest, abdomen, genitalia, skin, and back were normal. His head circumference was 49 cm (far < 5th centile), height was 98 cm (about 25th centile) and his weight was 15 kg (25th- 50th centile) at birth. He started walking at 1 2/12, had head support at the age of 7 months, and was sitting by 9 months of age. He had 4 words of speech at the age of 1 year.

He is the product of normal pregnancy with normal scans and foetal movements, and normal vaginal delivery. Birth weight was 3.100kg. He had mild neonatal jaundice and was incubated for 3 days for phototherapy.

Molecular genetic analysis

All *CHRD1* and *FOXC1* exons and intron-exon boundaries were directly Sanger sequenced from PCR amplicons as previously described [1,34]. No mutation was identified in *CHRD1* or *FOXC1* in the two affected brothers.

Discussion and Conclusion

MMR syndrome is a phenotypically heterogeneous condition, with megalocornea and ID as pathognomonic features. Other clinical manifestations include neurological, craniofacial, digital anomalies and so forth. The genetic cause of MMR is yet to be fully elucidated. The similar ratio of reported male to female patients indicates no sex bias and therefore suggests an autosomal recessive or a *de novo* inheritance mode [16, 5, 21, 24, 25]. Interestingly, a recent study identified a missense mutation, p.(Cys155Tyr) in the *CHRD1* gene in a male patient with a diagnosis of MMR syndrome [3]. However, extraocular phenotypes have not been observed in any previously reported MGC1 patients with confirmed *CHRD1* mutations. This finding suggests that in this patient, MMR may be a digenic condition, where *CHRD1* mutation accounts for the ocular phenotype, and the genetic cause of the extraocular phenotypes remains unexplained. *FOXC1* is a ubiquitously expressed transcription factor, which regulates cell viability and resistance to oxidative stress in the eye [35,36]. *FOXC1* mutations have been associated with a wide range of ASD, such as ARS, a genetically diverse group of developmental disorders, including peters anomaly, aniridia, and PCG, which affect several anterior segment structures of the eye, with a high risk of blindness due to glaucoma [37]. In addition to ocular findings, systemic anomalies such as ID, hypotonia, facial dysmorphism, and bilateral sensorineural deafness have been described in patients with 6p25 microdeletion, which encompassed the *FOXC1* gene [38]. These mutations were encountered to be associated with carcinogenesis mainly breast cancer and melanoma by activating MST1R/PI3K/AKT [39-40]. Follow up of affected brothers is done regularly by systemic clinical examination and some laboratory tests including full blood count and occult blood in stools.

In this study, two brothers diagnosed with MMR syndrome were recruited suggesting X-linked or recessive inheritance of the condition. No mutation was identified in the *CHRD1* or *FOXC1* genes by Sanger sequencing of the coding regions, however the genes cannot be fully excluded as copy number variations or mutations in non-coding regions were not tested using this approach. Due to the rarity of this condition, next generation sequencing (NGS) in a cohort of MMR patients is essential to identify the underlying genetic cause(s) of this poorly understood syndrome.

Funding

This work was funded by UCL Ophthalmology institute, London and National Research centre, Egypt.

References

- Webb TR, Matarin M, Gardner JC, Kelberman D, Hassan H, et al. (2012) X linked megalocornea caused by mutations in CHRD1 identifies an essential role for ventroptin in anterior segment development. *American journal of human genetics* 90: 247–259. [Link: https://goo.gl/7KKT9i](https://goo.gl/7KKT9i)
- Han J, Young JW, Frausto RF, Isenberg SJ, Aldave AJ (2015) X linked Megalocornea Associated with the Novel CHRD1 Gene Mutation p.(Pro56Leu*8). *Ophthalmic Genet* 36:145-148. [Link: https://goo.gl/ojz7Cv](https://goo.gl/ojz7Cv)
- Davidson AE, Cheong SS, Hysi PG, Venturini C, Plagnol V, et al. (2014) Association of CHRD1 mutations and variants with X-linked megalocornea, Neuhauser syndrome and central corneal thickness. *PLoS One*. 9: e104163. [Link: https://goo.gl/QN3LHq](https://goo.gl/QN3LHq)
- Gao WL, Zhang SQ, Zhang H, Wan B, Yin ZS (2013) Chordin-like protein 1. *Mol Med Rep* 7:1143-1148. doi: 10.3892/mmr.2013.1310. [Link: https://goo.gl/G4afjc](https://goo.gl/G4afjc)
- Del Giudice E, Sartorio R, Romano A, Carrozzo R, Andria G (1987) Megalocornea and mental retardation syndrome: two new cases. *Am J Med Genet* 26: 417-420. [Link: https://goo.gl/xHZchs](https://goo.gl/xHZchs)
- DelGiudiceE,SartorioR,RomanoA,CarrozzoR,AndriaG(1987) Megalocornea and mental retardation syndrome: clinical and instrumental follow-up of a case. *J Child Neurol* 21: 893-896. [Link: https://goo.gl/i65uVM](https://goo.gl/i65uVM)
- Ou-Yang L, Xiao SJ, Liu P, Yi SJ, Zhang XL, et al. (2015) Forkhead box C1 induces epithelial-mesenchymal transition and is a potential therapeutic target in nasopharyngeal carcinoma. *Mol Med Rep* doi 12: 8003-8009 [Link: https://goo.gl/JmNkxh](https://goo.gl/JmNkxh)
- Nishimura DY, Swiderski RE, Alward WL, Searby CC, Patil SR, et al. (1998) The forkhead transcription factor gene FKHL7 is responsible for glaucoma phenotypes which map to 6p25. *Nature Genetics*, 19:140–147. [Link: https://goo.gl/ukgKvk](https://goo.gl/ukgKvk)
- Lehmann OJ, Ebenezer ND, Jordan T, Fox M, Ocaka L, et al. (2000) Chromosomal duplication involving the forkhead transcription factor gene FOXC1 causes iris hypoplasia and glaucoma. *American Journal of Human Genetics*; 67:1129–1135. [Link: https://goo.gl/TbXoWz](https://goo.gl/TbXoWz)
- Nishimura DY, Searby CC, Alward WL, Walton D, Craig JE, et al. (2001) A spectrum of FOXC1 mutations suggests gene dosage as a mechanism for developmental defects of the anterior chamber of the eye. *American Journal of Human Genetics* 68: 364–372. [Link: https://goo.gl/4Z62tB](https://goo.gl/4Z62tB)
- Khan AO, Aldahmesh MA, Al-Amri A (2008) Heterozygous FOXC1 mutation (M161K) associated with congenital glaucoma and aniridia in an infant and a milder phenotype in her mother. *Ophthalmic Genetics* 29: 67–71. [Link: https://goo.gl/EXP9DQ](https://goo.gl/EXP9DQ)
- Fitch N, Kaback M (1978) The Axenfeld syndrome and the Rieger syndrome. *Journal of Medical Genetics* 15: 30–34. [Link: https://goo.gl/kfYPYM](https://goo.gl/kfYPYM)
- Alward WL (2000) Axenfeld-Rieger syndrome in the age of molecular genetics. *American Journal of Ophthalmology* 130: 107–115. [Link: https://goo.gl/3dT7aG](https://goo.gl/3dT7aG)
- Lines MA, Kozlowski K, Walter MA (2002) Molecular genetics of Axenfeld-Rieger malformations. *Human Molecular Genetics* 11: 1177–1184. [Link: https://goo.gl/88wAKG3](https://goo.gl/88wAKG3)
- Frank Y, Ziprkowski M, Romano A, Stein R, Katznelson MB, et al. (1973) Megalocornea associated with multiple skeletal anomalies: a new genetic syndrome?. *J Genet Hum* 21: 67-72. [Link: https://goo.gl/3DoLU9](https://goo.gl/3DoLU9)
- Neuhauser G, Kaveggia EG, France TD, Opitz JM (1975) Syndrome of mental retardation, seizures, hypotonic cerebral palsy and megalocorneae, recessively. *Z Kinderheilkd* 120: 1-18. [Link: https://goo.gl/gPtKf8](https://goo.gl/gPtKf8)
- Ohno K, Suzuki Y (1978) A case of the syndrome of megalocornea, mentalretardation and seizures (Neuhauser). *Shounika Rinshou* 31:1977–1979.
- Schmidt R, Rapin L (1981) The syndrome of mental retardation and megalocornea. *Am J Hum Genet* 30:90A. [Link: https://goo.gl/Etcp1v](https://goo.gl/Etcp1v)
- Raas-Rothschild A, Berkenstadt M, Goodman RM (1988) Megalocornea and mental retardation syndrome. *Am J Med Genet* 29: 221– 223. [Link: https://goo.gl/hbKq6v](https://goo.gl/hbKq6v)
- Grønbech-Jensen M (1989) Megalocornea and mental retardation syndrome: A new case. *Am J Med Genet* 32:468–469. [Link: https://goo.gl/4haUgD](https://goo.gl/4haUgD)
- Frydman M, Berkenstadt M, Raas-Rothschild A, Goodman RM (1990) Megalocornea, macrocephaly, mental and motor retardation (MMM). *Clin Genet* 38:149–154. [Link: https://goo.gl/AuhUUr](https://goo.gl/AuhUUr)
- Kimura M, Kato M, Yoshino K, Ohtani K, Takeshita K (1991) Megolocornea: mental retardation syndrome with delayed myelination. *Am J Med Genet*. 38: 132-133. [Link: https://goo.gl/EshVW6](https://goo.gl/EshVW6)
- Temtamy S, Abdel-Hamid J, Hussein F (1991) Megalocornea mental retardation syndrome (MMR): Delineation of a new entity (MMR-2). *Am J Hum Genet* 49: 125A. [Link: https://goo.gl/1k9LAq](https://goo.gl/1k9LAq)
- Santolaya JM, Griyalbo A, Delgado A, Erdozain G (1992) Additional case of Neuhauser megalocornea and mental retardation syndrome with retardation syndrome: An additional case. *Am J Med Genet* 52: 56 [Link: https://goo.gl/1k9LAq](https://goo.gl/1k9LAq)
- Verloes A, Journel H, Elmer C, Misson JP, Le Merrer M, et al. (1993) Heterogeneity versus variability in megalocornea-mental retardation (MMR) syndromes: Report of new cases and delineation of 4 probable types. *Am J Med Genet* 46: 132–137. [Link: https://goo.gl/wJE8SX](https://goo.gl/wJE8SX)
- Antinolo G, Rufo M, Borrego S, Morales C (1994) Megalocornea-mental Assignment of a locus (GLC3A) for primary congenital glaucoma (Buphthalmos) to 2p21 and evidence for genetic heterogeneity. *Genomics* 30: 171–7. [Link: https://goo.gl/wJE8SX](https://goo.gl/wJE8SX)
- Gibbs ML, Wilkie AOM, Winter RM (1994) Megalocornea, developmental retardation and dysmorphic features: Two further patients. *Clin Dysmorphol*; 3: 132–138. [Link: https://goo.gl/FJC6tu](https://goo.gl/FJC6tu)
- Barisic I, Ligutic I, Zergollern L (1996) Megalocornea-mental retardation syndrome: Report of a new case. *J Med Genet* 33: 882–883. [Link: https://goo.gl/zc6PtB](https://goo.gl/zc6PtB)
- Naritomi K, Chinen Y, Tohma T (1997) Megalocornea-mental retardation syndrome: An additional case report. *Jpn J Hum Genet* 42: 461–465. [Link: https://goo.gl/p9jBAK](https://goo.gl/p9jBAK)
- Tominaga N, Kondoh T, Kamimura N (1999) A case of megalocorneamental retardation syndrome complicated with bilateral sensorineural hearing impairment. *Pediatr Int* 41:392–394. [Link: https://goo.gl/HuJyTR](https://goo.gl/HuJyTR)
- Sarkozy A, Mingarelli R, Brancati F, Dallapiccola B (2002) The syndrome of mental retardation and megalocornea. *Am J Hum Genet* 30:90 A. [Link: https://goo.gl/HuJyTR](https://goo.gl/HuJyTR)
- Balci S, Teksam O, Gedik S (2002) Megalocornea, macrocephaly, mental and motor retardation: MMMM syndrome (Neuhauser syndrome) in two sisters with hypoplastic corpus callosum. *Turk J Pediatr* 44: 274-277. [Link: https://goo.gl/b9yrxW](https://goo.gl/b9yrxW)
- Derbent BM, Oto S, Alehan F (2004) Megalocornea-mental retardation (MMR or Neuhauser) syndrome: Another case associated with cerebral cortical atrophy and bifid uvula. *Genet Couns* 15: 477– 480. [Link: https://goo.gl/16G7QT](https://goo.gl/16G7QT)
- Mears AJ, Jordan T, Mirzayans F, Dubois S, Kume T, et al. (1998) Mutations of the forkhead/winged-helix gene, FKHL7, in patients with Axenfeld-Rieger anomaly. *American Journal of Human Genetics* 63: 1316–1328. [Link: https://goo.gl/STTSUx](https://goo.gl/STTSUx)



35. Pierrou S, Hellqvist M, Samuelsson L, Enerbäck S, Carlsson P (1994) Cloning and characterization of seven human forkhead proteins: binding site specificity and DNA bending. *The EMBO Journal* 13: 5002–5012. [Link: https://goo.gl/yop3rj](https://goo.gl/yop3rj)
36. Berry FB, Skarie JM, Mirzayans F, Fortin Y, Hudson TJ, et al. (2008) FOXC1 is required for cell viability and resistance to oxidative stress in the eye through the transcriptional regulation of FOXO1A. *Human Molecular Genetics* 17: 490–505. [Link: https://goo.gl/aQJXYS](https://goo.gl/aQJXYS)
37. Idrees F, Vaideanu D, Fraser SG, Sowden JC, Khaw PT (2006) A review of anterior segment dysgeneses. *Surv Ophthalmol.* 51: 213-231. [Link: https://goo.gl/pWGSyT](https://goo.gl/pWGSyT)
38. Kapoor S, Mukherjee SB, Shroff D, Arora R (2011) Dysmyelination of the cerebral white matter with microdeletion at 6p25. *Indian Pediatr.* 48: 727-729. [Link: https://goo.gl/BV9qY9](https://goo.gl/BV9qY9)
39. Xu YL, Yao R, Li J, Zhou YD, Mao F, et al. (2017) FOXC1 overexpression is a marker of poor response to anthracycline-based adjuvant chemotherapy in sporadic triple-negative breast cancer. *Cancer Chemother Pharmacol.* 79: 1205-1213. [Link: https://goo.gl/bCiPsP](https://goo.gl/bCiPsP)
40. Han B, Qu Y, Jin Y, Yu Y, Deng N, et al. (2015) FOXC1 Activates Smoothed-Independent Hedgehog Signaling in Basal-like Breast Cancer. *Cui XCell Rep.* 13: 1046-1058. [Link: https://goo.gl/mHNqri](https://goo.gl/mHNqri)

Copyright: © 2017 Gebril OH, et al. This is an open-access article distributed under the terms of the Creative Commons Attribution License, which permits unrestricted use, distribution, and reproduction in any medium, provided the original author and source are credited.

Citation: Gebril OH, Cheong SS, Hardcastle AJ, Abdelraouf ER, Eid SR, et al. (2017) Absence of CHRDL1 and FOXC1 sequence changes in two brothers with Megalocornea-Mental Retardation Syndrome. *J Neurol Neurol Sci Disord* 3(1): 028-032.